Saint-Petersburg State Pediatric Medical University, Saint-Petersburg, Russia

- Modern technologies
- in treatment of fecal incontinence in children

Komissarov Igor Alexeevich- Ph.D, M.D, Prof.
Kolesnikova Nadezda - Ph.D, M.D. Glushkova Victoria - M.D.

2013

Three physiological and anatomical factors are responsible for **ideal fecal continence:**

1. intestinal motility
2. anal and dystal rectal sensation
3. healthy anal sphincters

Usually these groups of patients have damage of factors of ideal fecal continence

- 1. patients after correction of anorectal malformations
- 2. patients after Hirschsprung disease correction
- 3. patients with neurogenic pelvic floor dysfunction due to myelomeningocele

These patients represent the **heaviest group of patients with fecal incontinence**

- At present we are limited in tools to impact on motility of rectosigmoid segment and sensitivity of anal channel

- Therefore adequate surgical correction of fecal incontinence and sphincter complex of rectum allow child achieve social adaptation.

Matherials and methods

Since 2004 to 2013 **186** patients with fecal incontinence have been treated in clinic of Saint Petersburg State Pediatric Medical University.

There were 126 patients with fecal incontinence after surgical correction of anorectal malformations, 30 patients after Hirschsprung disease surgical correction and 30 patients after myelomeningocele surgical management.

Clinical manifestation of organic fecal incontinence vary:

All patients have abnormalities of act of defecation:

- long delay of stool
- fecal incontinence
- combination of these symptoms
- “pseudo-incontinence" - overflow incontinence.

Methods of investigation

It is necessary to use:

- electrodiagnostic of external anal sphincter
- manometry of rectum or neorectum and anal channel
- irrigography

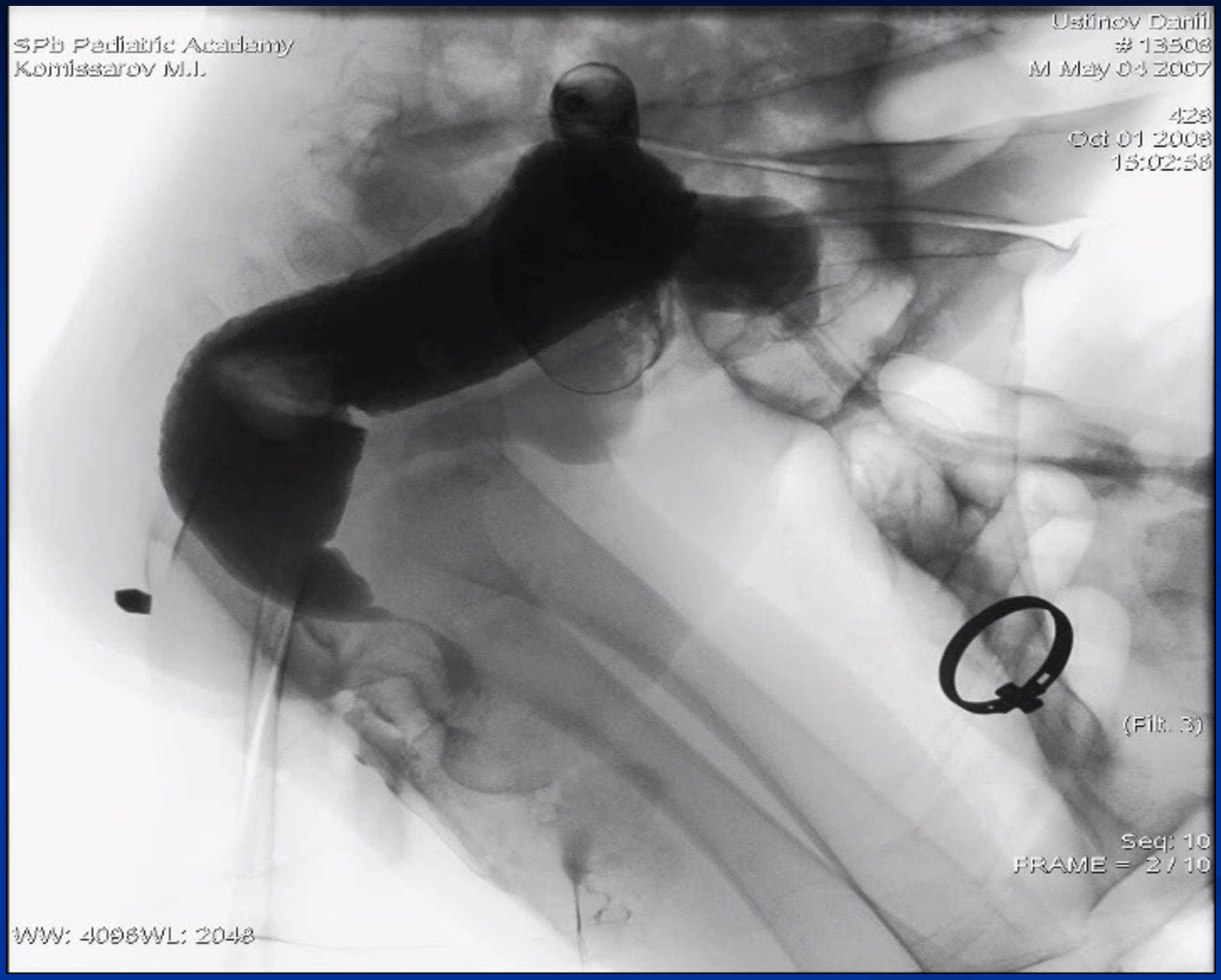
SPb Pediatric Academy
Komissarov M.I.
Ustinov Daniil
13508
M May 04 2007
428
Oct 01 2008
15:02:58
(Filt. 3)
Seq: 10
FRAME = 2 / 10
WW: 4096WL: 2048

To define anorectal angle we use ballonoproctogramm showing functional condition of puborectal muscle

A. – anorectal angle is 110 degrees (normal), B- anorectal angle is 155 degrees (pathological)

A. B.



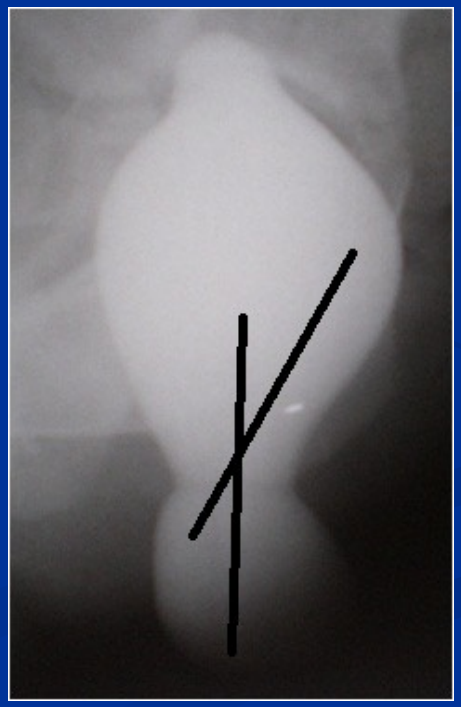

Spiral computer tomography of pelvic floor allows to visualize injury of external sphincter and levator muscle

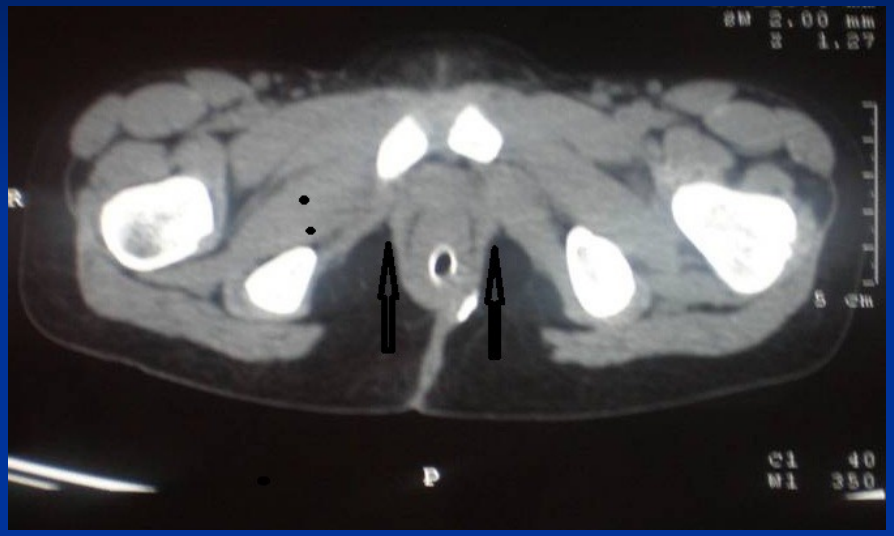

- Computer tomography of pelvic floor. A- puborectal muscle is preserved, B – right puborectal muscle is damaged (patient after correction of anorectal atresia)

Deformations of anorectal area (stenosis, protruding mucous, severe dislocation of anus and especially their combination) don't allow to estimate true degree of fecal incontinence or constipation, the damage of colon motility.

Therefore at the first step of surgical treatment it is necessary to remove stenosis of anus or protrusion of mucous.

Mucous protrusion (patient after correction of anorectal anomalies)

Methods of treatment of organic fecal incontinence

- We consider that patients without expressed deformations of anorectal area shall be treated conservativelly for a long time.

- Adaptation opportunities of children considerably raise with age and results of conservative therapy often surpass expectations.

Indications for surgery

- mucous protrusion and stenosis of anal channel resistant to dilatation
- deformations of anorectal area
- inefficiency of prolonged conservative treatment (not less than 3-5 years) at insufficiency of holding device of rectum.

Treatment of chronic colostasis (overflow incontinence) after correction of anorectal anomalies.

In case of megarectum and "overflow " fecal incontinence we use one-stage resection of megarectum and pull-through of a thick gut by transanal way without abdominal access. 4 patients (3,2%) after surgical correction of anorectal malformations underwent this type of surgical management.

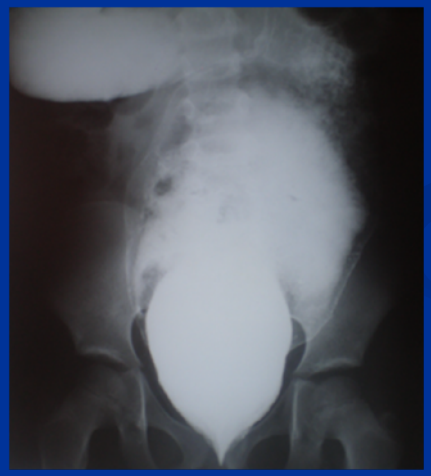

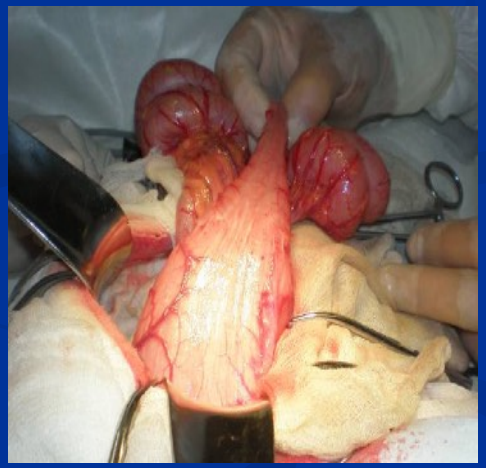

Megarectum after repair of low anorectal anomalies

Treatment of organic fecal incontinence (damage of puborectal musle).

Reconstruction of an anorectal angle

- Importance of normal anorectal angle in continence doesn't raise doubts.
- Sphincter reconstruction will not be successful if anorectal angle is more than 130 degrees.

Treatment of organic fecal incontinence.
Reconstruction of an anorectal angle. Sphincterolevatoroplastic

- In children with partial damage of levator and puborectal muscle (anorectal angle is 120-140 degrees) we use post-anal **sphincterolevatoroplasty**

- The aim of the operation is reduction of anorectal angle by means of shifting of anorectal connection up and forward. Thus the anal channel is extended, narrowed, condensed and the pressure in it is increased. Identification of muscular structures is facilitated by electrostimulation use. It is necessary to pass to levator and to sew their left and right portions layer-by-layer to the anal sphincter level

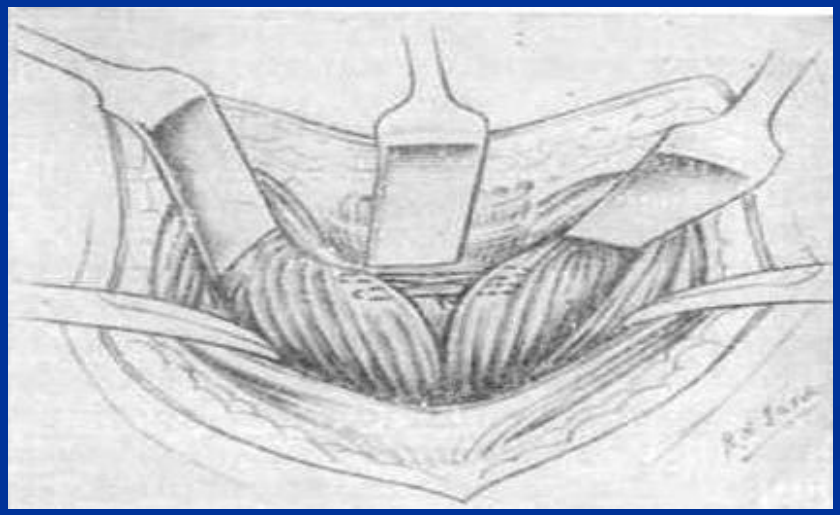

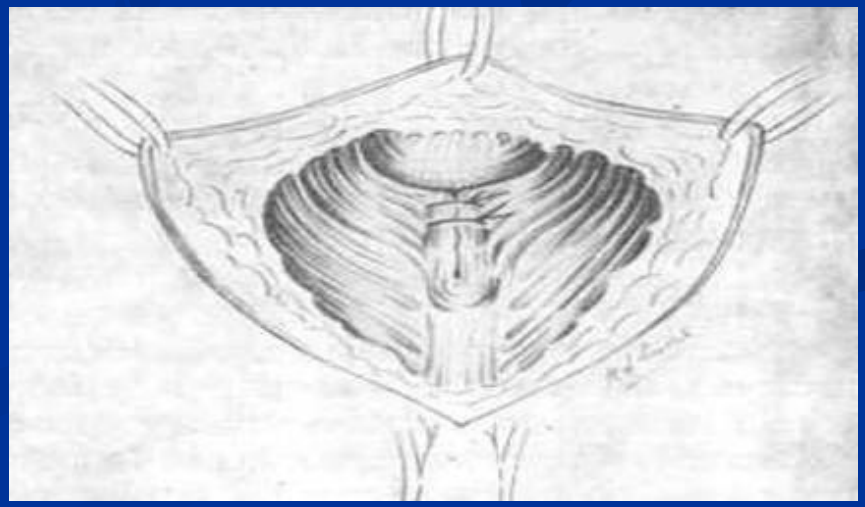

Reconstruction of anorectal angle.
Prosthetics of puborectal musle with the creation of anorectal angle

- In children with heavy damage of levator and puborectal muscle (anorectal angle is more than 140 degrees) we use prosthetics of puborectal musle with the creation of anorectal angle
- Produce two short (2-3cm) symmetrical cuts on both sides to the medial surface of the lower branches of pubic bones. Make tunnels on each side of the colon to pubics bones. Grafts are placed in a U - shaped loop at the level of anorectal connection and sutured to the periosteum of each of pubic bone. If at surgery there were any rectum muscle elements identified, spend their reconstruction (by type of Parks operation). Be sure transplant to be always proximal to the level of the external sphincter.

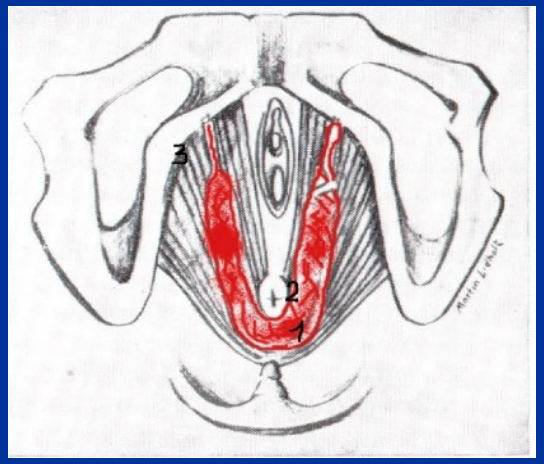

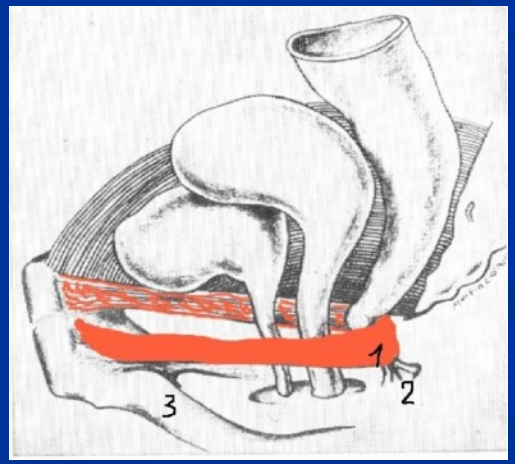

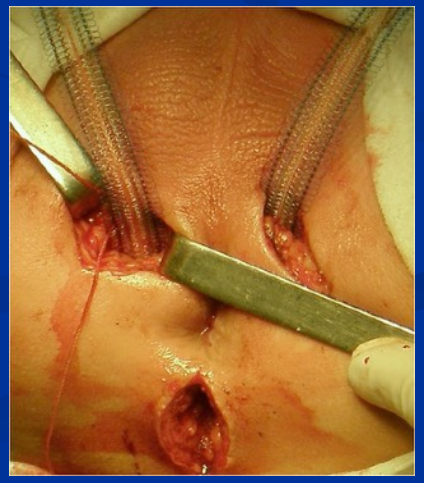

Last years in this operation we use allomatherials of porcine dermal collagen and polypropylene which are continuous and satisfactory models of functioning puborectal muscle and well adapt in patient tissues.

A. **B.**

- A - porcine dermal collagen prosthesis of puborectal musle. B. – polypropylene prosthesis of puborectal musle.

Reconstruction of an anorectal angle.
Operation prosthetic puborectal musle with the creation of anorectal angle

- Certainly **these operations** can't restore normal act of defecation however they **allow to transfer heavy fecal incontinence into light constipation.** Thus after a cleaning enema the child can remain "clean" throughout the day that considerably improves his quality of life.
- 20 patients (15,9%) after surgical correction of anorectal malformations, 30 % patients after surgical correction of myelomeningocele underwent reconstruction of anorectal angle with allogenic matherials.

Treatment of organic fecal incontinence

- Fecal incontinence in children can be caused by low base pressure in the anal channel due to damage of an internal sphincter and incomplete compression of anus.
- Manometric research reveals sharp decrease of base pressure in anal channel to 5 - 20 cm of water that is 39,5% of age norm.

In these cases we use injections of bulking agent «DAM+»

We inject it into a submucosal layer of anal channel on depth of 1 - 3 cm on "3, 6, 9, 12 hours" till its complete closure. We use from 8 to 50 ml of gel depending on the degree of anal channel gaping and age of a child. At the subsequent manometric control pressure in anal channel is 2 – 3 times increased that is more than 65% from age norm

Injections of bulking agent «DAM+»



Manometric investigations to (A) and after (B) using injections of “DAM”

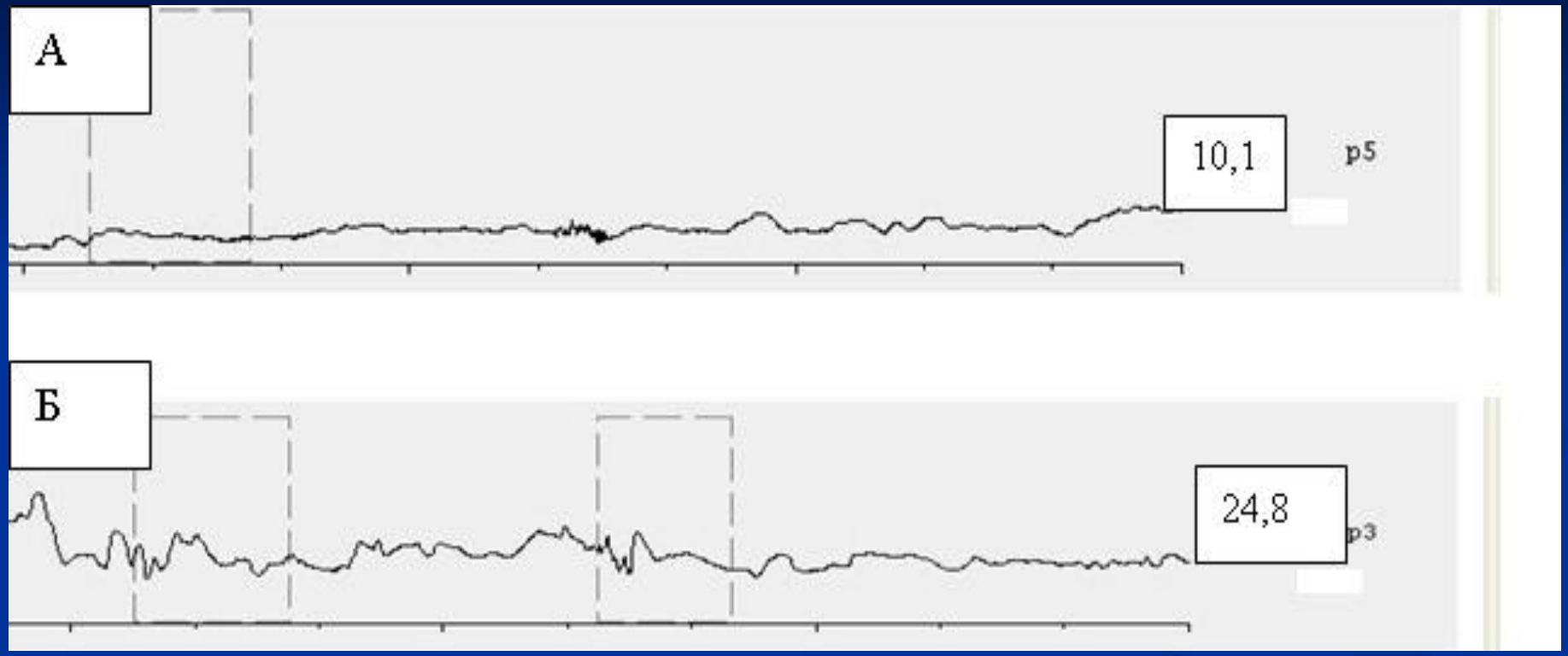

Modern surgeries indicated for children with defecation abnormalities and organic anal incontinence (after correction of anorectal atresia, Girshprung disease, neurogenic dysfunction of pelvic floor because of spinal hernia) may be divided into <u>4 groups</u>

- 1 . In case of severe damage of intestinal motility and stubborn constipation transanal resection of hypomotor intestine is indicated
- 2 . In case of anal sphincter are indicated:

A. operation with the use of local tissues - post-anal sphincterolevatoroplasty.

B. prosthetics of puborectal musle and creation of anorectal angle with the use of artificial transplants

C. gel plastic of anal channel.

Thanks - for attention